



Jan Sanjeevni Trust

Hands to Serve - Heart to Love

Reg. No. 1061

PAN No. AADTJ0816E

Jan Sanjeevni Trust Registration No: 1061/2017

Jan Sanjeevni Trust PAN No: AADTJ0816E

Jan Sanjeevni Trust Website: www.jstngo.org

Jan Sanjeevni Trust E-mail : we@jstngo.org

| | |
|-----------------------------|---------------------------------|
| PATIENT NAME | Vihaan (Baby of Priyanka) |
| GURDIAN | Ashish Katiyar |
| D.O.B/ SEX | 6 Feb 2026, Male |
| DISEASE NAME | Congenital Heart Disease |
| TREATMENT HOSPITAL | Sir Ganga Ram Hospital |
| REG NO. | 3693917 |
| DEPARTMENT NAME | Pediatric Cardiac Science |
| TREATMENT COST | Seven Lakh Rupees Only |
| GURDIAN'S OCCUPATION | Farmer |
| ADDRESS | Behta Aira, lakhimpur kheri, UP |



@jansanjeevnitrust



Jan Sanjeevni Trust



Jan Sanjeevni Trust



उत्तर प्रदेश सरकार
GOVERNMENT OF UTTAR PRADESH
 चिकित्सा एवं स्वास्थ्य विभाग
DEPARTMENT OF MEDICAL AND HEALTH
 ग्राम पंचायत भण्डसरिया
GRAMA PANCHAYAT BHANDSARIA

जन्म प्रमाण-पत्र
BIRTH CERTIFICATE

(जन्म और मृत्यु रजिस्ट्रीकरण अधिनियम, 1969 की धारा 12/17 तथा उत्तर प्रदेश जन्म और मृत्यु रजिस्ट्रीकरण नियम 2002 के नियम 8/13 के अन्तर्गत जारी किया गया)
 (ISSUED UNDER SECTION 12/17 OF THE REGISTRATION OF BIRTHS AND DEATHS ACT, 1969 AND RULE 8/13 OF THE UTTAR PRADESH REGISTRATION OF BIRTHS & DEATHS RULES 2002)

यह प्रमाणित किया जाता है कि निम्नलिखित सूचना जन्म के मूल लेख से ली गई है जो कि ग्राम पंचायत भण्डसरिया तहसील लखीमपुर जिला खेरी राज्य/संघ प्रदेश उत्तर प्रदेश, भारत के रजिस्टर में उल्लिखित है।

THIS IS TO CERTIFY THAT THE FOLLOWING INFORMATION HAS BEEN TAKEN FROM THE ORIGINAL RECORD OF BIRTH WHICH IS THE REGISTER FOR GRAMA PANCHAYAT BHANDSARIA OF TAHSIL/BLOCK LAKHIMPUR OF DISTRICT KHERI OF STATE/UNION TERRITORY OF UTTAR PRADESH, INDIA

नाम / NAME: VIHAAN

लिंग / SEX: MALE

आधार संख्या / AADHAAR NUMBER:

जन्म तिथि / DATE OF BIRTH:

06-02-2026

SIXTH-FEBRUARY-TWO THOUSAND TWENTY SIX

जन्म स्थान / PLACE OF BIRTH:

BHANDSARIA, LAKHIMPUR, KHERI, UTTAR PRADESH, 262701

माता का नाम / NAME OF MOTHER:

PRIYANKA VERMA

पिता का नाम / NAME OF FATHER:

ASHISH KATTIYAR

माता का आधार नंबर / AADHAAR NUMBER OF MOTHER:

XXXX-XXXX-5443

पिता का आधार नंबर / AADHAAR NUMBER OF FATHER:

XXXX-XXXX-3409

बच्चे के जन्म के समय माता-पिता का पता / ADDRESS OF PARENTS AT THE TIME OF BIRTH OF THE CHILD:

BEHTA, AIRA ESTATE, AIRA, DHAURAHARA, KHERI, UTTAR PRADESH, 262722

माता-पिता का स्थायी पता / PERMANENT ADDRESS OF PARENTS:

BEHTA, AIRA ESTATE, AIRA, DHAURAHARA, KHERI, UTTAR PRADESH, 262722

पंजीकरण नंबर / REGISTRATION NUMBER:

H252509143810900214

पंजीकरण तिथि / DATE OF REGISTRATION:

18-02-2026

टिप्पणी (यदि कोई हो) / REMARKS (IF ANY):

जारी करने की तिथि / DATE OF ISSUE:

18-02-2026

Updated on: 18-02-2026 01:52:19



"This QR code can be used to check the authenticity of the certificate"

अधिकारी के हस्ताक्षर / SIGNATURE OF ISSUING AUTHORITY:

उत्तर प्रदेश स्वास्थ्य विभाग

Department of Medical & Health

ग्राम पंचायत भण्डसरिया

BHANDSARIA, LAKHIMPUR, KHERI, UTTAR PRADESH

"प्रत्येक जन्म एवं मृत्यु का पंजीकरण सुनिश्चित करें / ENSURE REGISTRATION OF EVERY BIRTH AND DEATH"



SGRH/DM/MC/FE/Trtmt/E-218

Sir Ganga Ram Hospital : New Delhi

MEDICAL CERTIFICATE FOR COST OF TREATMENT

Certificate No: DM/MC/FE/Pediatric Cardiac Sciences 2026

(Department)

(Running No.)

| | | |
|----|-----------------------------------------------------------------------------------------------------------|---------------------------------------------------------------------------------------|
| 1 | Name | : Vihaan (aka B/o Priyanka Verma) |
| 2 | Age | : 1 month 11 days |
| 3 | Sex | : Male |
| 4 | Adhaar No | : |
| 5 | Patient Registration No | : 3693917 |
| 6 | Date patient examined | : 17/03/2026 |
| 7 | Brief Clinical Summary (Only relevant salient features like Nature of illness Symptoms Probable cause) | : Cyanosis (SpO ₂ = 76%) |
| 8 | Diagnosis: Cyanotic CHD | : DORV, PM-VSD, additional mid muscular VSD Severe PS + long segment LPA stenosis. |
| 9 | Treatment Planned | : Duct is severely restrictive PA plasty + BT shunt (w/line; on pump) |
| 10 | Inpatient / Outpatient | : Inpatient |
| 11 | Duration of hospitalization if any | : |
| 12 | Cost of Treatment | : Rs 7,00,000/- |
| 13 | Purpose for which medical certificate issued | : Financial Assistance |
| 14 | Medical Certificate Addressed to | : G. M. Fund, UP |

Atishay

Patients Signature / Thumb impression

Date: 17/03/2026

Rajendra Prasad Singh

Dr. (Prof.) RAJA JOSHI
MCh (CVS), Fellow (Peds Card Surg. USA)
Senior Consultant, Pediatric Cardiac Surgeon
Sir Ganga Ram Hospital
MCI Reg. No 11934 DMC Reg No 26626

Date: 17/3/2026

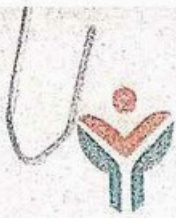Director Medical

Dr. SUCHI KATOCH
Medical Superintendent
Sir Ganga Ram Hospital
Rajinder Nagar New Delhi-110050

Dr. JODY ARORA
Dr. ANIL KUMAR PANDEY
NOTARY ADVOCATE
MCI Reg. No. 11934 DMC Reg No. 26626

Date: 17/3/2026

Validity upto: 17/5/2026



SIR GANGA RAM HOSPITAL
Trust of Generations

Dr. (Prof) Raja Joshi

MBBS, MS, MCh, (CTVS)

Fellowship (Cleveland Clinic, USA)

Senior Consultant Neonatal & Pediatric Cardiac Surgeon

Chairman, Department of Pediatric Cardiac Sciences

Sir Ganga Ram Hospital, New Delhi

MCI Reg. No. 11934, DMC Reg. No. 26626



Vihaan (aka B/O Priyanka Verma)

0y 1m 11d / Male

REG NO: 3693917

PCS ID: --

DOB: Feb. 6, 2026

WEIGHT: 3.10 kg

HEIGHT: 51.00 cm

HEART RATE (BPM): 137

SPO2: 76 %

REF. DOCTOR: Dr. G.K. Singh

DATE: March 17, 2026, 2:07 p.m.

PERSONAL HISTORY:

Term, AGA (B wt= 2.5Kg)

PRESENT COMPLAINTS:

Saturations have dropped to 76%

DIAGNOSIS:

SS, LC, B/L SVC, DORV, Commitable PM-VSD + additional mid-muscular small VSD, Severe PS and Long segment LPA stenosis

CLINICAL FINDINGS:

This time has gained weight approximately 800-900 gms over 30 days

ECHOCARDIOGRAM:

Same findings as before with further increase in degree of RVH and concern for the future LVOT tunnel

MEDICATIONS:

TAB INDERAL / CIPLAR 10MG (1/8TH TABLET) TDS

CONTINUE IRON DROPS

REMARKS/ADVICE:

Procure CMRF letter from DMS office

NEXT FOLLOW-UP:

R/A 2 weeks for planning Pulm CTA (BUN and Creatinine) under c/o Dr Anil Kumar-PCS

(TO COME FOR FOLLOW-UP AS ADVISED WITH APPOINTMENT OR REPORT ANY ABNORMAL SYMPTOMS)

25:1 ml. FF ↑ volume

6° Simyl MCT OIL per feed
gradually ↑ by 2° every
3days till 15° per-feed

S.G.R.H - Rajinder Nagar, New Delhi - 60, Ph. : 011-42251700,
42251800, 42254000, Fax No. : 91-11-25861002, EPBX : 011-25750000
OPD Room No. F-57, Timings : 9.00 am - 5.00 pm Monday to Saturday
For Appointment Call : +91 9873818788, OPD ☎ 011-42251757,
Mobile : +91 9811118187, e-mail : dr.raja_joshi@yahoo.com





Department of Pediatric Cardiac Sciences Echocardiography Report

B/O Priyanka Verma
DOB: Feb. 6, 2026
REF. DOCTOR: Dr. G.K. Singh

0y 1m 11d / Male
WEIGHT: 3.10 kg

REG NO: 3693917
HEIGHT: 51.00 cm

PCS ID: --
BSA: 0.201

DATE OF ECHO: March 17, 2026
ECHO TYPE: Trans Thoracic Echocardiogram

PATIENT LOCATION: OPD

Cardiac Position

Abdominal Situs Solitus.
Levocardia.

Cardiac Segments

Atrial Situs Solitus.
D-loop ventricle.
AV concordance.
Two patent AV Valves.

Double Outlet Right ventricle

Normally related great arteries.

Veins

Systemic Venous drainage - Bilateral SVC, LSVC to CS
Normal Pulmonary Venous drainage.

Atria

Interatrial septum- Small OS ASD (Left to Right shunt)

Dilated RA

LA size- Long Anterior Appendage

Atrioventricular Canal

Normal Mitral valve.
Normal Tricuspid valve.

Ventricles

Normal Left ventricle.

Dilated Right ventricle- Significant Right ventricular Hypertrophy,

RV Free wall 4.5mm

Interventricular septum- Large Malaligned VSD with Outlet extension (8mm), Ratable Aorta

Additional Mid muscular VSD(Bidirectional shunt) (2.5mm)



Ventricles

Normal Left ventricle.

**Dilated Right ventricle- Significant Right ventricular Hypertrophy,
RV Free wall 4.5mm**

**Interventricular septum- Large Malaligned VSD with Outlet extension (8mm), Routable Aorta
Additional Mid muscular VSD(Bidirectional shunt) (2.5mm)**

| | |
|-----------|--------------|
| IVSd (mm) | IVSd z-score |
| 9.0 | +8.31 |
| PWd (mm) | PWd z-score |
| 4.0 | +0.91 |

Conotruncus

**LVOT and aortic valve- Systolic Doming of Aortic valve, Functionally Bicuspid Aortic valve
70 - 90% Aortic Override, Sub Aortic VSD on Routing size 4.5 - 5mm
RVOT and pulmonary valve - RVOT Peak gradient 100mmHg,
(Infundibular + valvular) Severe PS (Small Antegrade flow)**

| | |
|------------------------------|---------------------------------|
| Aortic Valve annulus (mm) | Aortic Valve annulus z-score |
| 12 | +6.49 |
| Pulmonary Valve annulus (mm) | Pulmonary Valve annulus z-score |
| 4.5 | -5.33 |

Great Arteries

Normal ascending aorta, arch and descending aorta.

Confluent branch pulmonary arteries- RPA 4.0mm

LPA proximal 1.3mm, Long segment LPA proximal stenosis, LPA distal 4.0mm

Long Tortuous Vertical PDA from Arch (1-2mm), Left to Right shunt

Peak gradient 85mmHg

No Coarctation.

| | |
|----------------------|-------------------------|
| Ascending Aorta (mm) | Ascending Aorta z-score |
| 13 | +3.85 |

Function

Normal RV function.

Normal LV function.

Effusion

No pericardial effusion.

INTERPRETATION

- DOUBLE OUTLET RIGHT VENTRICLE
- LARGE MALALIGNED VSD (Routable Aorta)
ADDITIONAL MID MUSCULAR VSD
- PROXIMAL LONG SEGMENT LPA STENOSIS
- SIGNIFICANT RIGHT VENTRICULAR HYPERTROPHY
- BILATERAL SVC
- DILATED RA/ RV
- GOOD BIVENTRICULAR FUNCTION

Dr. Neeraj Aggarwal

MD (Pediatrics), Fellow Ped Cardiology
Sr Consultant, Pediatric Cardiologist
SIR GANGA RAM HOSPITAL

Dr. Mridul Agarwal

MD (Pediatrics), FNB Ped Cardiology
Sr Consultant, Pediatric & Fetal Cardiologist
SIR GANGA RAM HOSPITAL

Dr. Jasleen Kaur

MD (Pediatrics), DrNB Ped Cardiology
Associate Consultant, Pediatric Cardiologist
SIR GANGA RAM HOSPITAL

Report typed by: Pooja Kumari



SIR GANGA RAM HOSPITAL
Trust of Generations

Dr. (Prof) Raja Joshi

MBBS, MS, MCh, (CTVS)
Fellowship (Cleveland Clinic, USA)

Senior Consultant Neonatal & Pediatric Cardiac Surgeon
Chairman, Department of Pediatric Cardiac Sciences
Sir Ganga Ram Hospital, New Delhi
MCI Reg. No. 11934, DMC Reg. No. 26626



Vihaan (aka B/O Priyanka Verma) 0y 1m 28d / Male REG NO: 3693917 PCS ID: --
DOB: Feb. 6, 2026 WEIGHT: 3.60 kg HEIGHT: 51.00 cm
HEART RATE (BPM): 122 SPO2: 76 %
REF. DOCTOR: Dr. G.K. Singh
DATE: April 3, 2026, 4:18 p.m.

PERSONAL HISTORY:

Term, AGA (B wt= 2.5Kg)

DIAGNOSIS:

SS, LC, B/L SVC, DORV, Commitable PM-VSD + additional mid-muscular small VSD, Severe PS and LPA ostial stenosis (1.8mm) with distal hypoplasia (3.1mm), RPA is adequate (5mm)

CLINICAL FINDINGS:

Mild irritability

INVESTIGATIONS:

Pulm CTA done @ SGRH on 1-4-2026: Reviewed by me
SS, LC, B/L SVC,
DORV, VSD, Severe PS
LPA ostial stenosis (1.8mm) with distal hypoplasia (3.1mm),
RPA is adequate (5mm)
Right kidney is crossed and ectopic

ECHOCARDIOGRAM:

Last echo done on previous visit (17-3-2026) demonstrated increase in degree of RVH and "concern" for the future LVOT tunnel

MEDICATIONS:

TAB CIPLAR 10MG (DISSOLVE 10MG TABLET IN 10ML WATER & GIVE 4 ML =4MG) TDS
FERIKIND DROPS 0.3ML OD
VIT D-3 0.5ML OD

REMARKS/ADVICE:

Plan: LPA rehabilitation and increase oxygenation by LMBTTS

NEXT FOLLOW-UP:

Fix date when ready

(TO COME FOR FOLLOW-UP AS ADVISED WITH APPOINTMENT OR REPORT ANY ABNORMAL SYMPTOMS)

S.G.R.H - Rajinder Nagar, New Delhi - 60, Ph. : 011-42251700,
42251800, 42254000, Fax No. : 91-11-25861002, EPBX : 011-25750000
OPD Room No. F-57, Timings : 9.00 am - 5.00 pm Monday to Saturday
For Appointment Call : +91 9873818788, OPD ☎ 011-42251757,
Mobile : +91 9811118187, e-mail : dr.raja_joshi@yahoo.com

For Online Consult, Doctor ID : 53

myFollowUp

Available on the App Store | Get it on Google Play



SIR GANGA RAM HOSPITAL

Trust of Generations



H-2008-0017
Since June 16, 2008



MC - 2194

Clinical Laboratory Services Department of Biochemistry

Name : MASTER B/O PRIYANKA , Age/Sex : 8 Wks/Male
 Registration No. : 3693917 Ward No. :
 Lab Request No. : 9926085280 Room No. :
 Episode No. : OP16029016 Location Type: Out Patient
 Location : CENTRAL INVESTIGATION CENTRE Collected On : 31 MAR 2026 09:38AM
 Referred By : Dr. Raja Joshi Received On : 31 MAR 2026 10:59AM
 Ext. Doctor : Reported On : 31 MAR 2026 11:56AM
 Specimen : Blood Released by : Dr Reetika Saini
 Printed on : 31 MAR 2026 02:00PM

| Investigation | Results | Units | Bio.Ref.Interval | Test Method |
|-------------------|---------|-------|------------------|-------------------------|
| BUN, SERUM | 13.80 | mg/dL | (4.00-19.00) | Enzymatic (Urease/GLDH) |
| CREATININE, SERUM | 0.34 | mg/dL | (0.17-0.42) | Jaffe Kinetic (IDMS) |

-----{END OF REPORT}-----

Note:- (C) after result of a test indicates, it is critical. Needs Attention

1. This is a Computer generated report, No Signature required.
2. Content of this report is only an opinion, not the diagnosis.
3. The report shall not be reproduced, except in full, without permission.

<<< Page: 1 of 1 >>>



CT REPORT

| | | | |
|--------------|-----------------|-----------------|--------------------|
| Patient Name | :B/O PRIYANKA , | Age/Sex | :1Months/M |
| Reg. No. | :3693917 | Ward No. | : |
| Episode No. | :OP16034107 | RoomNo. | : |
| Imaging No. | :18381253/15 | Executed On | :01-Apr-2026 08:48 |
| Location | :CT SCAN | Location Type | :OPD |
| Referred By | :Dr. Raja Joshi | External Doctor | : |

CT PULMONARY ANGIOGRAPHY:

Post-contrast helical CT pulmonary angiography was performed using 0.9 x 128 mm acquisition on Phillips Ingenuity CT after intravenous injection of non-ionic contrast medium. Scans were obtained in the plain, arterial and venographic phases. 3D MIP reconstructions were also obtained.

Clinical Details: Patient is a known case of DORV, VSD, severe PS and LPA stenosis and bilateral SVCs.

CECT THORAX:

Thymus is defined.

Trachea and tracheal bifurcation appear normal. No mediastinal or hilar lymphadenopathy noted. No significant tracheobronchial compression noted. Mediastinal tubular structures are defined.

Lungs are clear and well expanded. No pleural effusion seen.

Screening of the upper abdominal viscera reveal an ectopic right kidney, overlying the aorta.

The vertebral bodies appear unremarkable with no evidence of an obvious skeletal anomaly.

ANGIOGRAPHIC FINDINGS:

There is situs solitus with levocardia.

There is a communication between the atrium. There are two communications between the ventricles suggestive of VSDs. The right atrium and right ventricle are dilated.

The aorta arises from the right ventricle. The ascending aorta measures approximately 13.8 mm. The arch is left sided and shows a bovine branching pattern with a combined origin of the right brachiocephalic and the left common carotid arteries, followed by the left subclavian artery. It is normal in caliber. The descending aorta also appears normal.

CT REPORT

| | | | |
|--------------|-----------------|-----------------|--------------------|
| Patient Name | :B/O PRIYANKA , | Age/Sex | :1Months/M |
| Reg. No. | :3693917 | Ward No. | : |
| Episode No. | :OP16034107 | RoomNo. | : |
| Imaging No. | :18381253/15 | Executed On | :01-Apr-2026 08:48 |
| Location | :CT SCAN | Location Type | :OPD |
| Referred By | :Dr. Raja Joshi | External Doctor | : |

The main pulmonary artery arises from the right ventricle. It is markedly narrowed and measures approximately 3.9 mm in diameter. It shows normal division into confluent right and left pulmonary arteries. The right pulmonary artery measures approximately 5 mm in diameter. The left pulmonary artery is narrowed to approximately 1.8 mm in the proximal aspect for a length of approximately 7 mm. Thereafter, the left pulmonary artery measures approximately 3.1 mm just before the branching. These show normal lobar, segmental and subsegmental branches.

The superior and inferior pulmonary veins bilaterally show normal drainage into the left atrium. Bilateral innominate veins continue as the SVCs. The right sided SVC and the suprahepatic IVC show normal drainage into the right atrium. The left sided SVC drains into the coronary sinus.

IMPRESSION: CT findings could be consistent with ASD, VSD, DORV, marked stenosis main pulmonary and left pulmonary arteries, bilateral SVCs.

Note is made up of ectopic crossed right kidney.

SUGGEST: Clinical Correlation

Anurag
Dr. Anurag Yadav
Consultant Radiologist

MT-Kamalpreet Kaur



Sir Ganga Ram Hospital

Rajinder Nagar, New Delhi-110060

INVOICE

Sir Ganga Ram Pharmacy

(Drug License Nos. : DL-RAJ-115931, DL-RAJ-115932, DL-RAJ-115933, DL-RAJ-115934, DL-RAJ-115935, DL-RAJ-115936)

Bill No: SGRH/PHC/14/26-27

Bill Date: 01/04/2026, 02:24:23

Status: Bill

GST Reg. No: 07AABTS4366E1Z1

Patient Name: B / O PRIYANKA

Patient Reg. No: B / O PRIYANKA

Prescribed By: Dr. Raja Jishi (GAA6312) (Sr. Consultant) ()

Printed By: Vandana Verma (GAA9545)

Issued On: April 01, 2026

| Sr. No. | Item | HSN | Batch | Expiry | MRP | Rate | Qty | GST % | Disc | Value | |
|----------------------------------|----------------------------------------------------------------------------|----------|------------|------------|--------|--------|------|-------------------------------|------|----------------------|---------|
| 1 | Neoflon Pro (24 G) - Bd | 90183930 | 5274638 | 2028-09-30 | 390.00 | 371.43 | 3.00 | 5.00 | 0.00 | 1170.00 | |
| 2 | Stopcock 3 way (70876.20 - vygon) | 90189099 | 180424FE | 2029-04-18 | 246.00 | 234.29 | 2.00 | 5.00 | 0.00 | 492.00 | |
| 3 | Lectroath IV extension tubing (100 cm) - Vygon 1155.10 | 90189099 | 270325EK | 2030-03-27 | 315.00 | 300.00 | 1.00 | 5.00 | 0.00 | 315.00 | |
| 4 | Mucomix 200 mg Injection (N - Acetylcysteine) | 30049099 | IACNA1502 | 2028-05-31 | 25.23 | 24.03 | 3.00 | 5.00 | 0.00 | 75.99 | |
| 5 | TEGADERM 1610 DRESSING - 3M | 30051020 | R02250914 | 2028-01-31 | 194.06 | 184.82 | 2.00 | 5.00 | 0.00 | 388.12 | |
| 6 | Microdrip Iv Set (Pedia Drip Plus) - Romsons | 90189099 | K26A020060 | 2030-12-31 | 311.00 | 296.19 | 1.00 | 5.00 | 0.00 | 311.00 | |
| 7 | Easyport 500 ml Injection Two Port - Eurohead (Dextrose 5% + NaCl 0.45%) | 30049099 | 1118752P | 2028-10-31 | 309.38 | 294.85 | 1.00 | 5.00 | 0.00 | 309.38 | |
| Total Amount | | | | | | | | | | 3061.19 | |
| Less Discount | | | | | | | | | | 0.00 | |
| Payable Amount (In words) | | | | | | | | three thousand sixty one only | | Total Payable | 3061.00 |

GST Summary

| GST % | Taxable Amt | CGST Amt | SGST Amt | Total GST | Total Amount |
|--------------|----------------|--------------|--------------|---------------|----------------|
| 5.00 | 2915.43 | 72.88 | 72.88 | 145.76 | 3061.19 |
| Total | 2915.43 | 72.88 | 72.88 | 145.76 | 3061.19 |

Payment Detail

| Type | Machine | Amount |
|------|---------|---------|
| Cash | | 3061.00 |

Note :

- All Prices are inclusive of taxes
- Refunds of medicines only within 15 days from purchase date on submission of original bill
- No Refunds will be done for cutting strips / cold chain items
- No refunds without original bill
- All disputes subject to Delhi jurisdiction

Prepared By:-

Vandana
Vandana Verma (GAA9545)



SIR GANGA RAM HOSPITAL

RAJINDER NAGAR, NEW DELHI-110060
PHONE: 011-42254000 (30 Lines); 011-35125600 (30 Lines); Fax: 25861002
GSTIN No.: 07AABTS4366E12H, HOSPITAL PAN No.: AABTS 4366E

SIR GANGA RAM HOSPITAL
CT-MR
BILL CUM RECEIPT

and click on Patient Portal. To visit www.srg.org

Reg. No. : 3693917
OPD No. : OP16034107
Name : MASTER B/O PRIYANKA
Age : 8 M
Address : VILL BEHTA POST
AIRA BEHTA
LAKHIMPUR KHIRI
UTTAR PRADESH
UTTAR PRADESH
Phone : 7607989214
Location : CT SCAN

Bill No. : 2026-2027/1A/D/00000136
Bill Date : 10/10/2026
Sex : Male
Internal Ref. No. : 30881
Hosp/PSU Ref. :

External Ref. :
GSTIN : 07AABTS4366E12H
CAC Code : 999316


| No. | Particulars | Unit | Price | Amount |
|-----|-----------------------------------------------------|------|----------|----------|
| 1 | CT ANGIOGRAPHY THORAX AND DESCENDING/THORACIC AORTA | 1 | 19500.00 | 19500.00 |

Total : 19500.00
Amount Paid : 19500.00

(Received a sum of Rupees Nineteen Thousand Five Hundred only)

Payment Details

| Sr No | Mode | Particulars | Amount |
|-------|------|-------------|----------|
| 1 | Cash | | 19500.00 |
| Total | | | 19500.00 |



For Cancellation / Refund of the Bill, any identity Proof in the form of Photo ID, Aadhar Card, Pan Card, Driving License, Passport is mandatory

: PEDIATRIC
paediatric
25-2026/0
2/2026 12



SIR GANGA RAM HOSPITAL

Trust of Generations

GSTIN : 07AABTS 4366 E1ZH
SAC Code : 999316

OPD BILL CUM RECEIPT

Reg. No. : 3693917
OPD No. : OP16037356
Name : MASTER VIHAAN
Age/Sex : 8 W/Male
Address : VILL BEHTA POST
AIRA BEHTA
LAKHIMPUR KHIRI
UTTAR PRADESH
UTTAR PRADESH

Consultant : PEDIATRIC CARDIAC SCIENCE
Department : Paediatric Cardiology
Bill No. : 2026-2027/Ca/O/0002572
Bill Date : 01/04/2026 04:05PM
Hosp/PSU Ref: SELF

Location : PRIVATE OPD CLINIC

| No. | Particulars | Unit | Price | Amount |
|-----|--------------------------------------------------|------|---------|---------|
| 1 | SHORT DURATION SEDATION IN PCS ICU DOCTOR FEE | 1 | 3090.00 | 3090.00 |

Total : 3090.00
Amount Paid : 3090.00

(Received with thanks from MASTER VIHAAN , a sum of Rupees Three Thousand
Ninety only)

Payment Details

| Sr No | Mode | Particulars | Amount |
|-------|------|-------------|---------|
| 1 | Cash | - | 3090.00 |
| Total | | | 3090.00 |

Signature
Date

For Cancellation / refund of the bill, any identity Proof in the form of Photo ID / Aadhar Card / PAN Card / Driving License is Mandatory
Kindly process any refund related issue within 15 days only.

Reg No- 3693917



Department of Pediatric Cardiac Sciences

Sir Ganga Ram Hospital


Rajinder Nagar, New Delhi – 110060

Received with thanks a sum of (Twenty-Five Thousand Rupees only (Rs. 25,000/-)

From..... Vihaan aka B/O Priyanka Verma (9670989213/7607989214).....

In favor of Advanced Booking for Admission on 26.04.2026 and Surgery 27.04.2026.

Date: 16.04.2026


Signature

Note:- Non Refundable

F PCS on 13.04.2026 by Ashish Katiyar



DR. NEERAJ AGGARWAL

MD, (Peds), FNH, RGHHS (Pediatric Cardiology)
Senior Consultant Pediatric Cardiologist
E-mail : drneeraj_12@yahoo.co.in
DMC Regn No. : 25394

DR. MRIDUL AGARWAL

MD (Peds), FNB (Pediatric Cardiology) National Board
Senior Consultant Pediatric Cardiologist
E-mail : drmridul@hotmail.com
DMC Regn No. : 35769

DR. JASLEEN KAUR

MD, (Peds), DrNB (Pediatric Cardiology)
Associate Consultant Pediatric Cardiologist
E-mail : dr.jasleen34@gmail.com
DMC Regn No. : 62646

24/04/2026

D.O.B - 06/02/2026

Vihaan (aka B/o Priyanka Verma)

2 months / Male

W = 4.3 kg

SpO₂ = 71%

HR = 121

DORV, VSD, PS
LPA Aortic Coarctation

Bil SCL

Bovine Aorta

→ aortic RT
Kidney

Echo

- DORV

- VSD

- Jctd with PM expansion

- Severe LPA stenosis.

- LTAch

- Jctd PDA to LPA

Adv:

Admission ↓ PCS
in cat-III

Dodoli
29/4/26



Sir Ganga Ram Hospital

SGRH/Fin Consl/F-215

Financial Counselling

Specialty PCS Admitting Consultant Dr Raja Joshi

| | | | | | | | |
|---------------------------------------|---------------------------------------------|------------------------------------|-------------------------------------------------|--------------------------------|--------------------------------|-------------------------------------------|-------------------------------------|
| Patient Name | <u>VIHAAN (B/O PRIYANKA VERMA)</u> | | | | | | |
| Age | <u>DOB =</u> | <u>6.2.2026</u> | | | | | |
| Sex | <u>male</u> | | | | | | |
| Paying Status | <input type="checkbox"/> TPA | <input type="checkbox"/> CORPORATE | <input checked="" type="checkbox"/> SELF PAYING | | | | |
| Registered Mobile No. | <u>9670989213</u> | | | | | | |
| Provisional/ Final Diagnosis | <u>DORV, VSD, PS, severe CPA stenosis</u> | | | | | | |
| Admission Status: | <input checked="" type="checkbox"/> Planned | | <input type="checkbox"/> Emergency | | | | |
| Date of Admission: | <u>26/4/2026</u> | | | | | | |
| Surgery (ies) / Treatment (s) Planned | <u>Left med BTTS</u> | | | | | | |
| Desired Bed Category | <input type="checkbox"/> Premium Suite | <input type="checkbox"/> Suite | <input type="checkbox"/> Deluxe | <input type="checkbox"/> Cat 1 | <input type="checkbox"/> Cat 2 | <input checked="" type="checkbox"/> Cat 3 | <input type="checkbox"/> DAY CARE # |

FINANCIAL ESTIMATE

CHARGES

| | | | |
|-----------------------------------------------------------------------|------------------------------|---|----------|
| Hospitalization | Approx Days: | @ | |
| Intensive Care, if any | Approx Days: | @ | |
| Major Investigations | | | |
| Operation / Procedure | <u>→ 4 Lakhs</u> | | |
| OT Charges | <u>Stay (ICU) 20-25k/day</u> | | |
| PAC + Anesthetist fee | | | |
| Surgeon Fee | | | |
| Implant (s), if any | <u>wound = 1.5-10k/day</u> | | |
| Major Drugs / Consumables, if any | | | |
| Other (Consultant visit, Dietician, MRD, Equipment, Blood/Components) | | | |
| TOTAL | APPROXIMATE | | ₹ |

EXCLUSIONS FROM PACKAGE

- CT/MRI ANALYSIS
- NCP AND
- (ABDOMINAL)
- DRUGS
- PERI
- SP
- (IG/TPN)
- OVERSTAY BEYOND PACKAGE

DAY CARE ADMISSION PATIENT MAY REQUIRE FURTHER HOSPITALISATION IN PATIENTS INTEREST AS PER DECISION OF CONSULTANT
 *Alternative Medicine, Cataract Surgery, Heart Rehab, Dialysis, Lithotripsy, Minor OT, Ventilator charges are same in all categories

(Shaded area to be filled by treating Consultant)

The estimate is based on past observation for this Surgery / Procedure / Treatment, Any change in treatment/another specialty consultation / unforeseen circumstances necessitating additional investigation and treatment will increase costs. Robotic surgery will have higher charges. Upgradation of bed / room will invite higher charges from date of admission. Critical care charges range from Rs. 50,000-80,000 or even higher per day based on intensity of treatment/ use of specific equipment. Packages have INCLUSIONS and EXCLUSIONS. Package rate is limited to a specific period of treatment only, and treatment beyond the specified period will be charged as per actuals. Final Bill may vary based on length of stay / change in / additional treatment given/ use of special drugs / equipment in best interest of the patient . I HAVE READ /HAVE BEEN EXPLAINED THE ABOVE IN A LANGUAGE THAT I UNDERSTAND AND I ACCEPT TO PAY HOSPITAL BILL RAISED FOR ME/ MY PATIENT

DATE : 24/4/26

SIGNATURES : [Signature] PATIENT/RELATIVE [Signature] CONSULTANT [Signature] FINANCIAL COUNSELLOR

